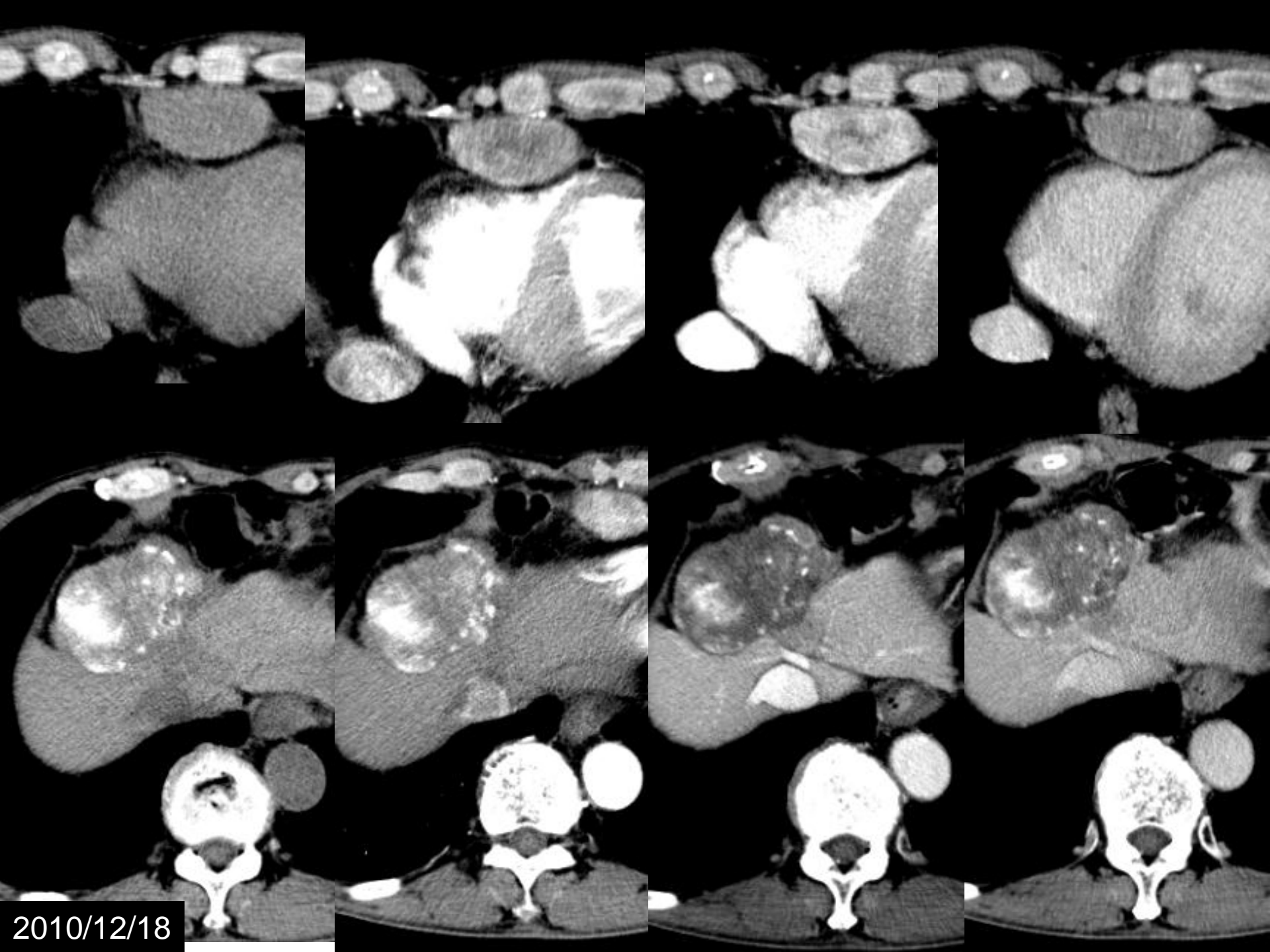


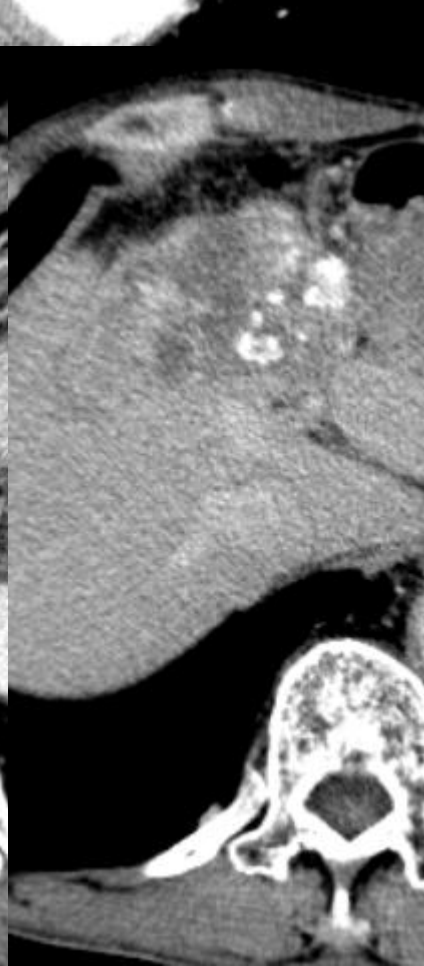
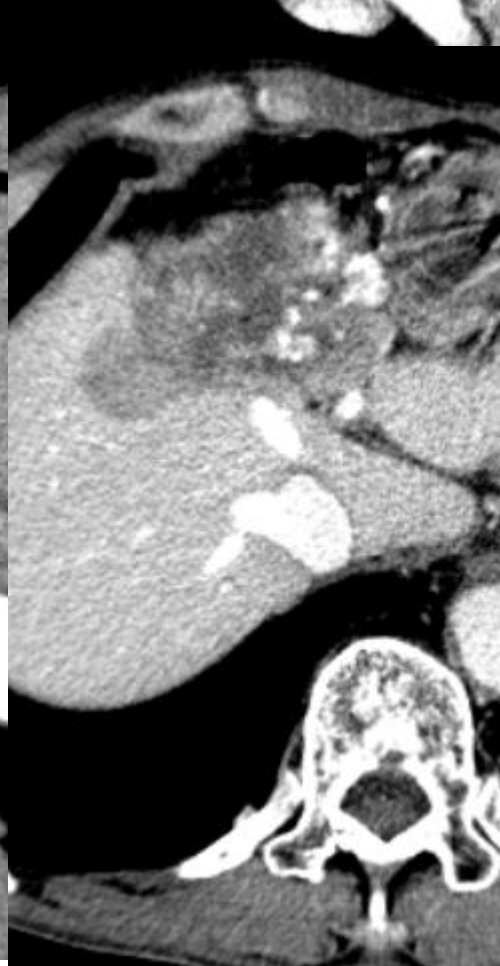
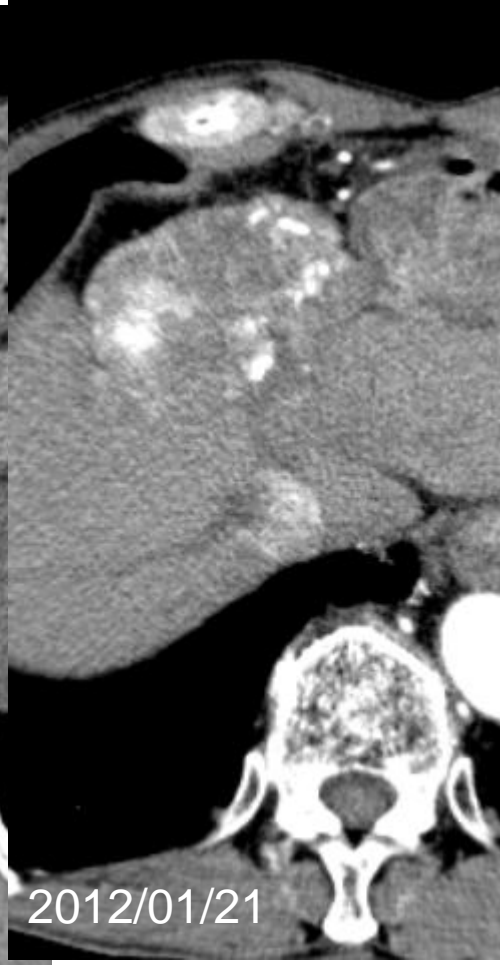
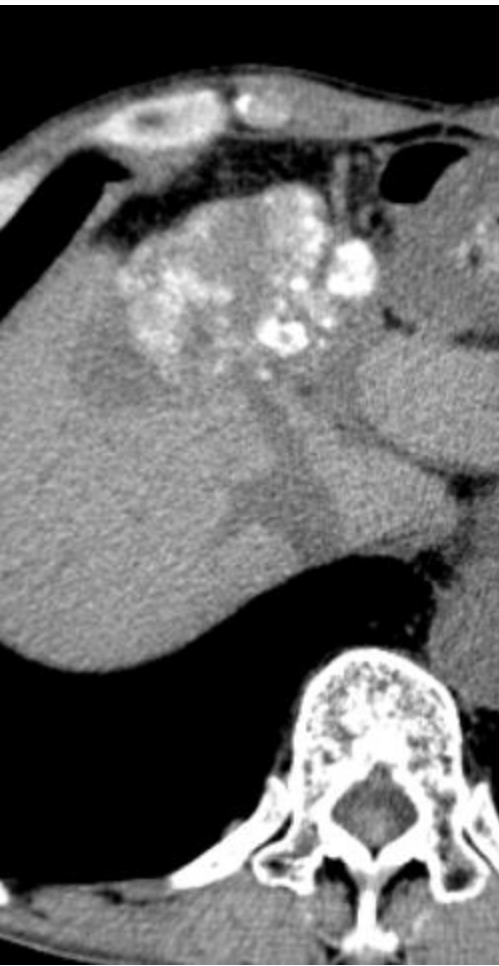
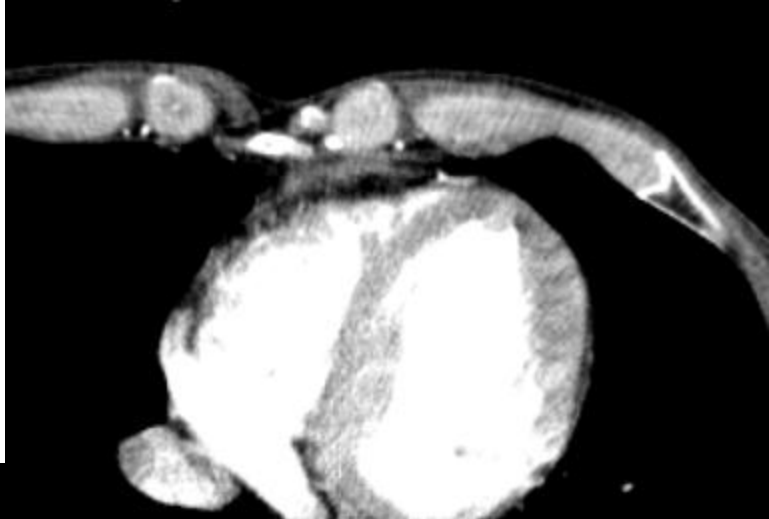
HCC:大網動脈出血

79M

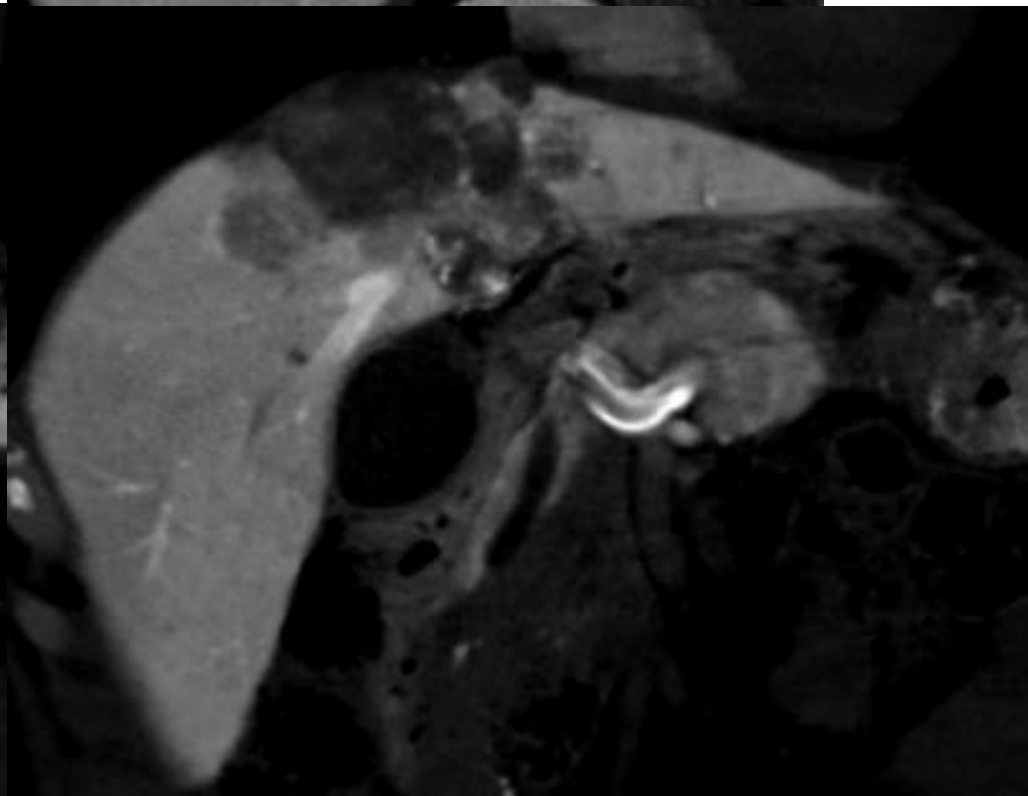
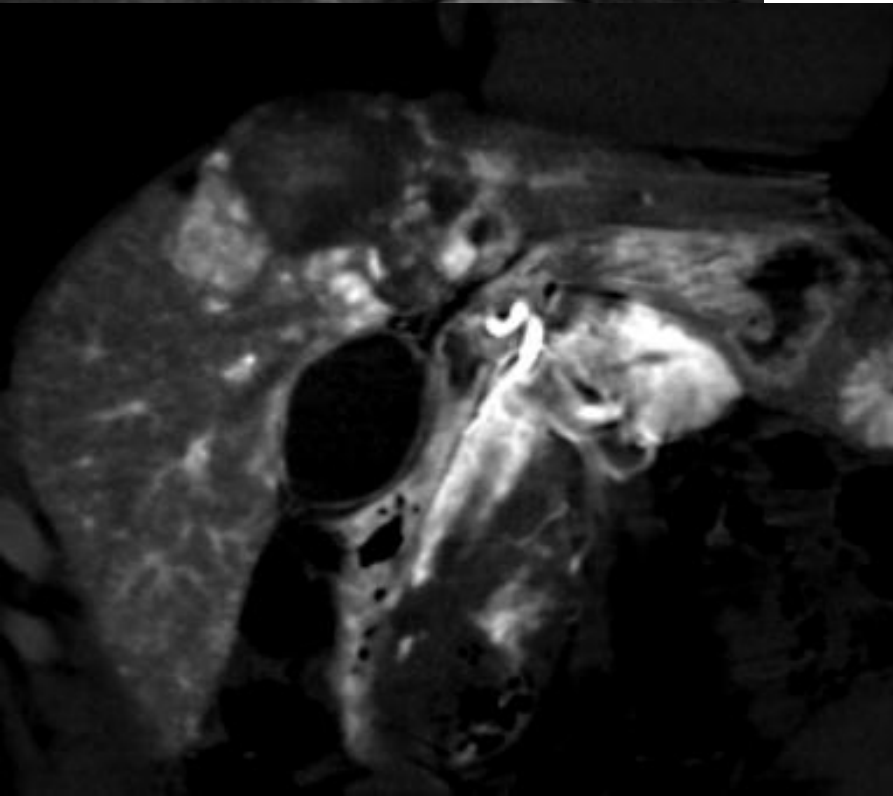
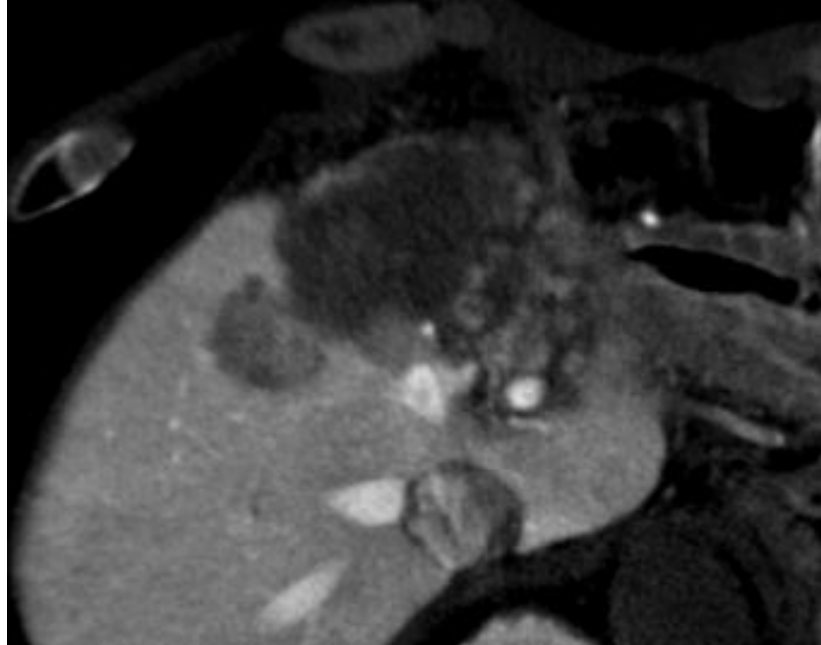
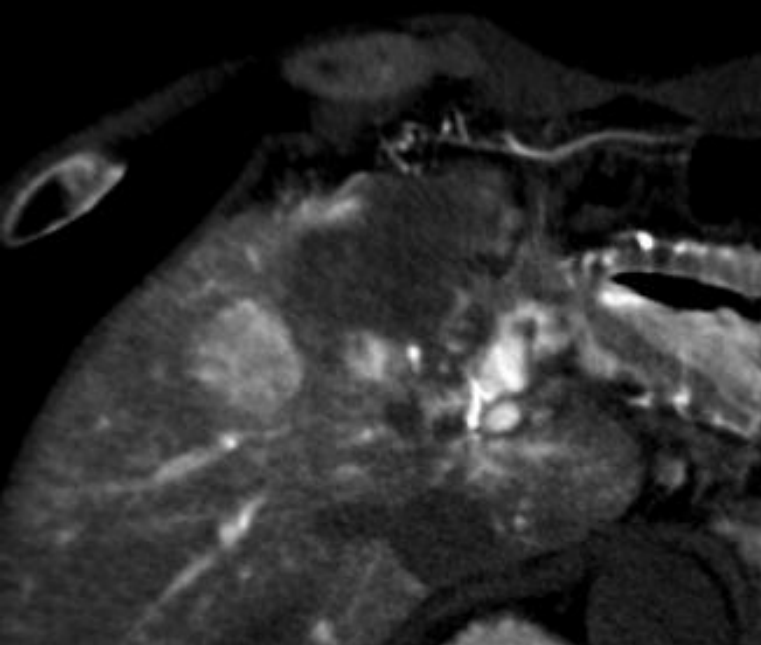
- 2003/02 HCCと診断
- 2003/02/26 TACE-1
- 2005/03/09 TACE-2
- 2005/06/29 TACE-3
- 2008/06/25 TACE-4
- 2011/02 心臓周囲リンパ節転移切除
- 2012/03/16 TACE-5

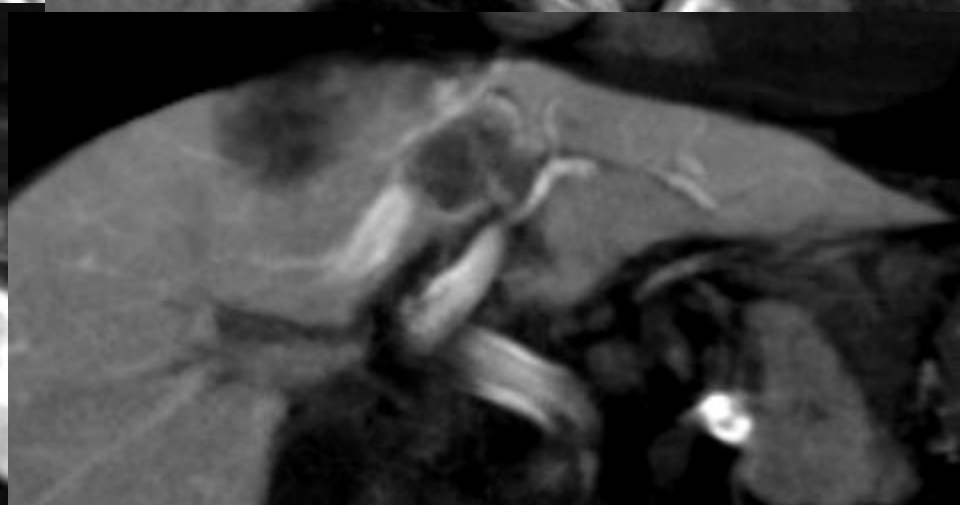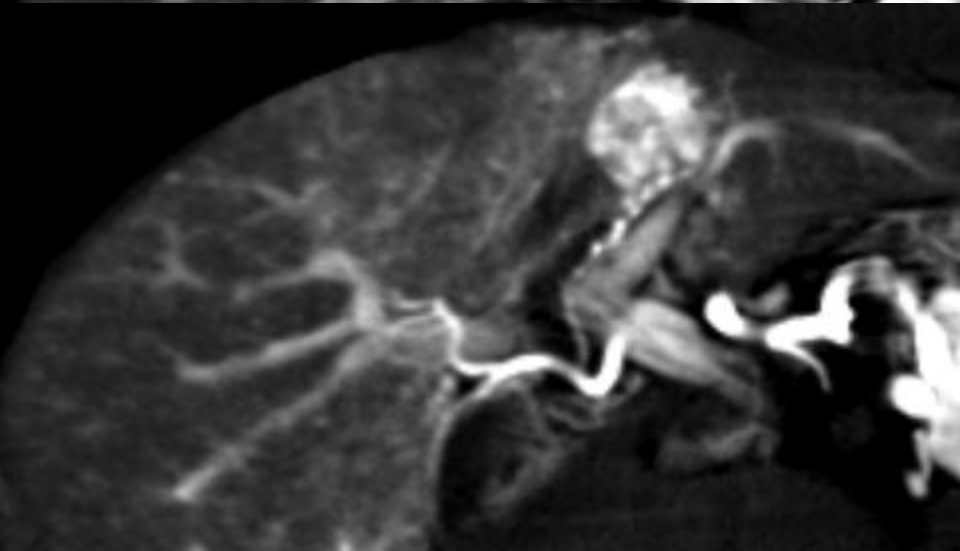
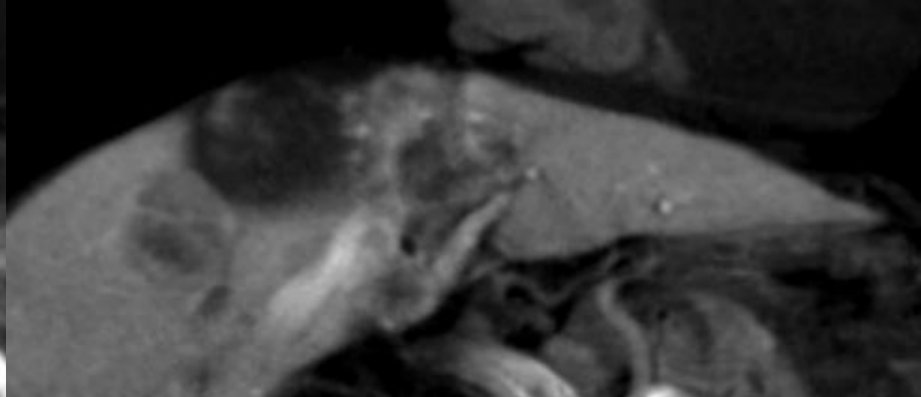
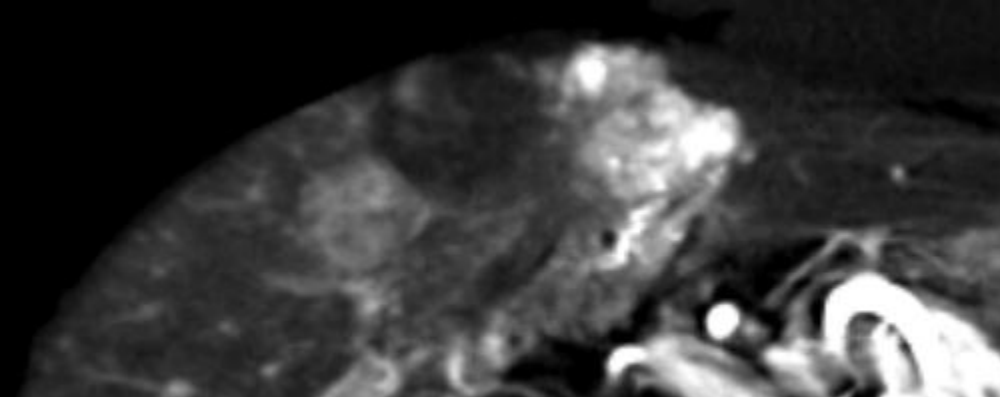
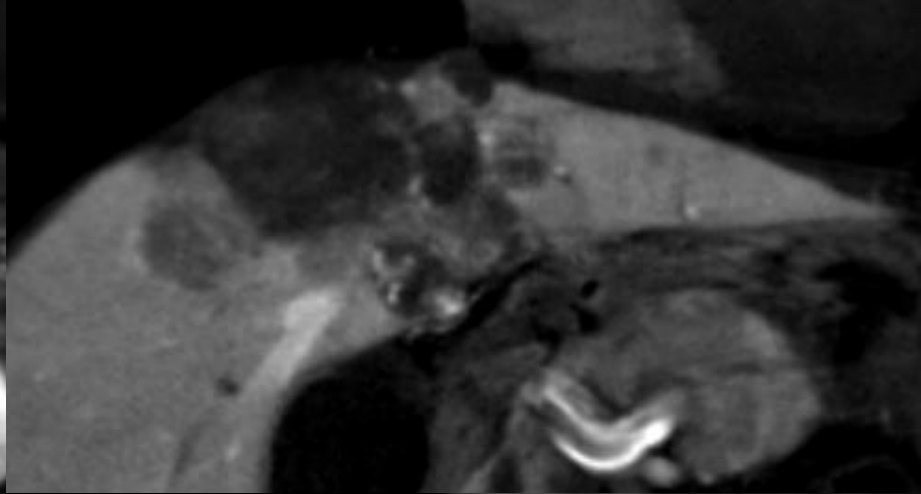
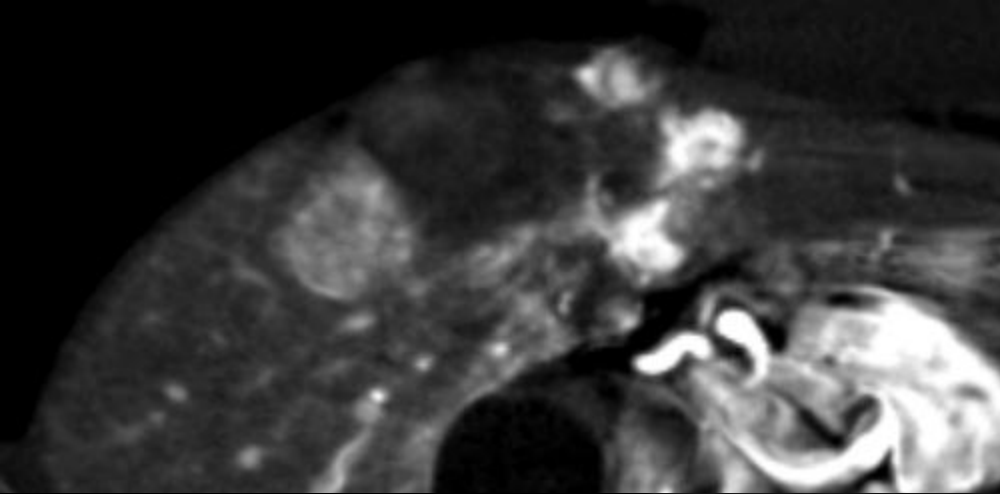


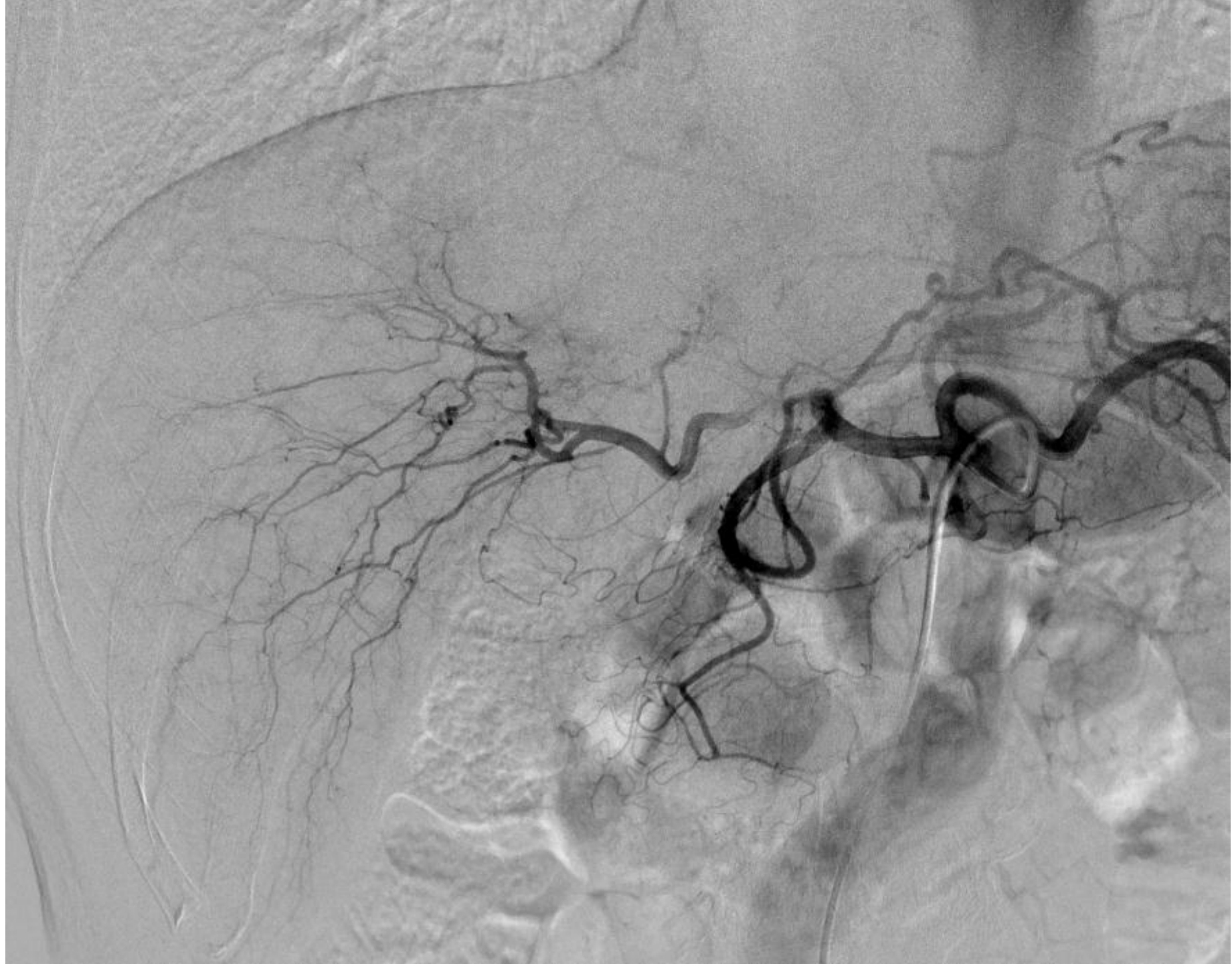2010/12/18

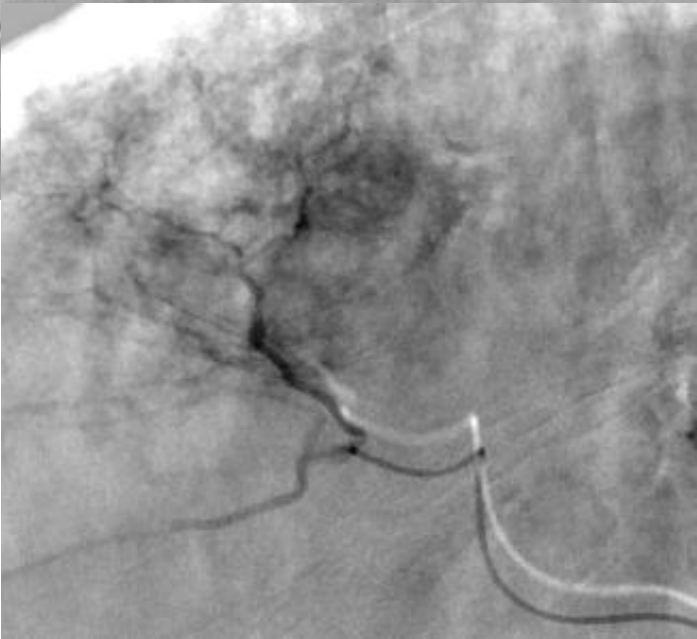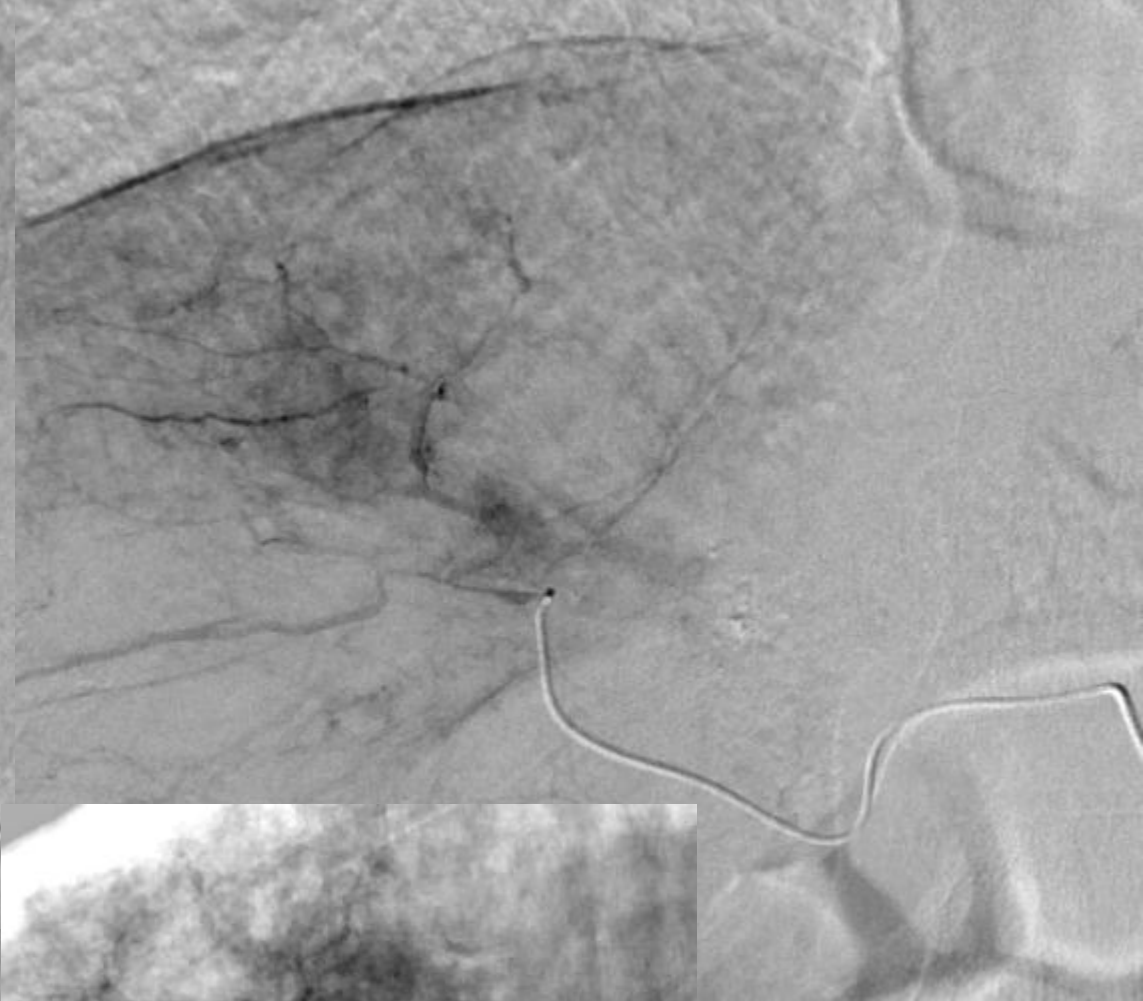

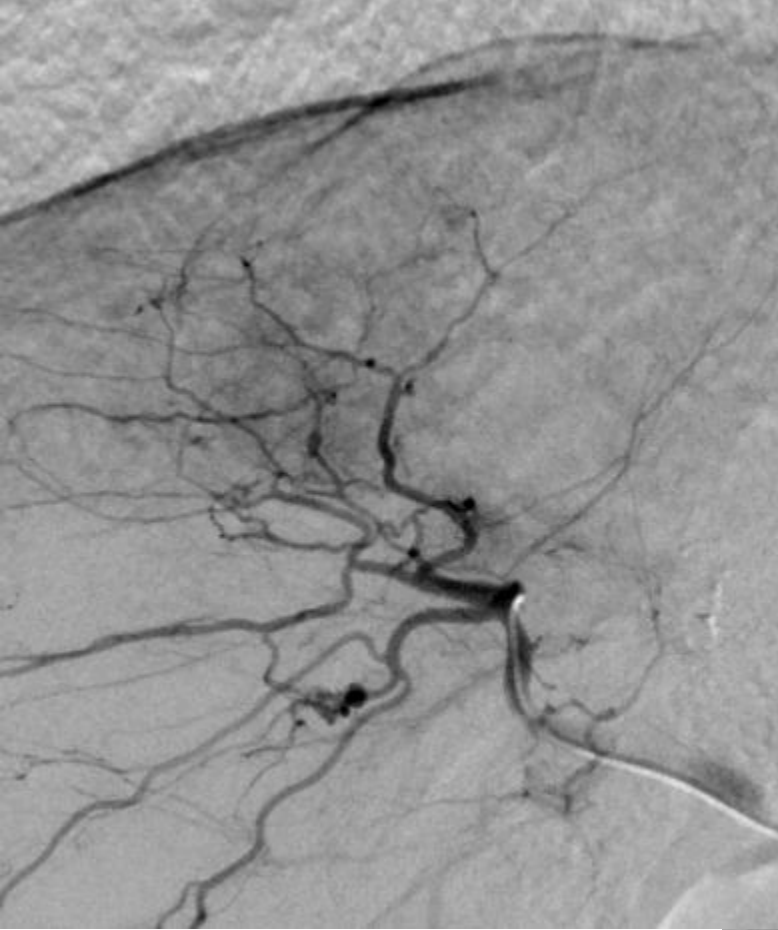
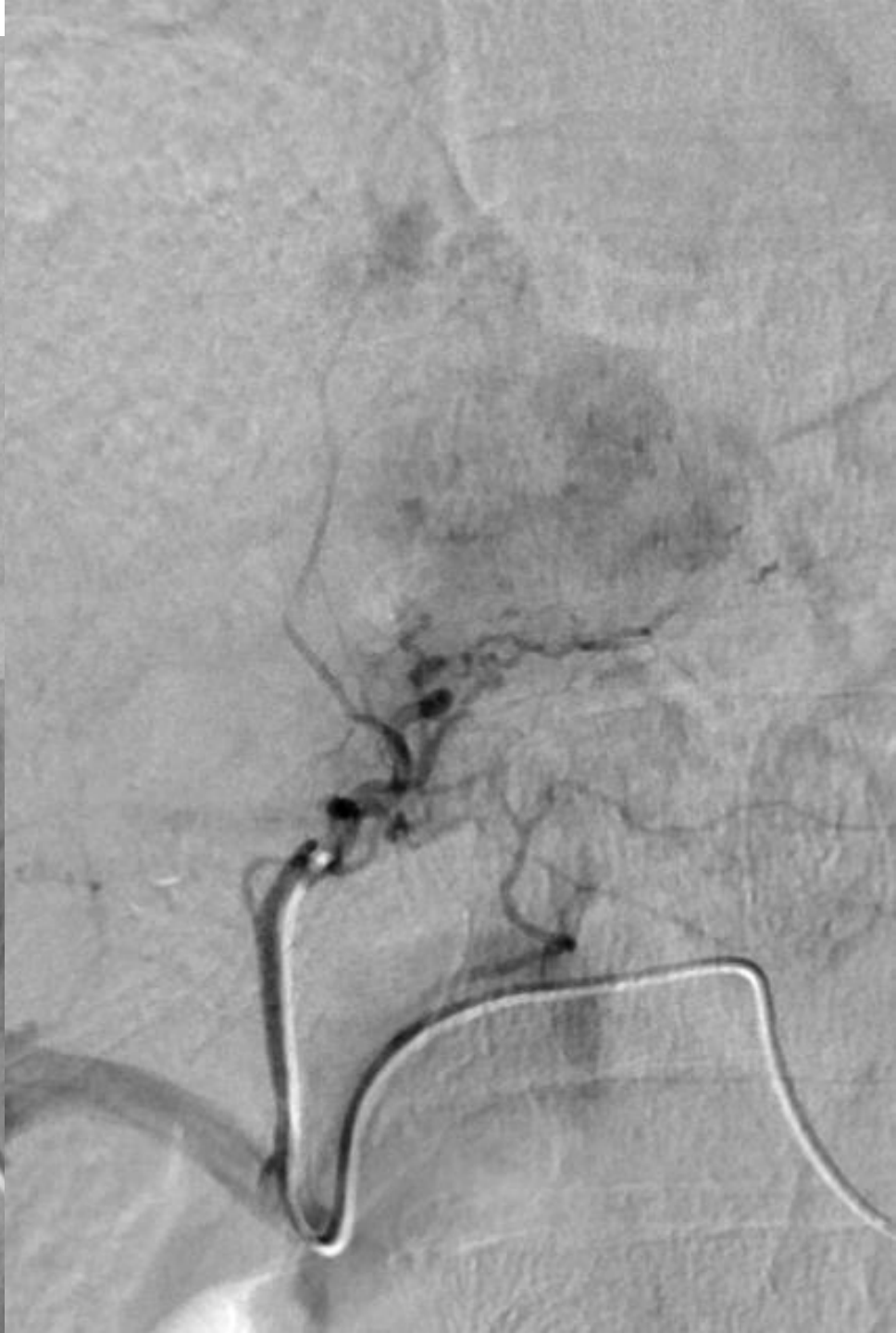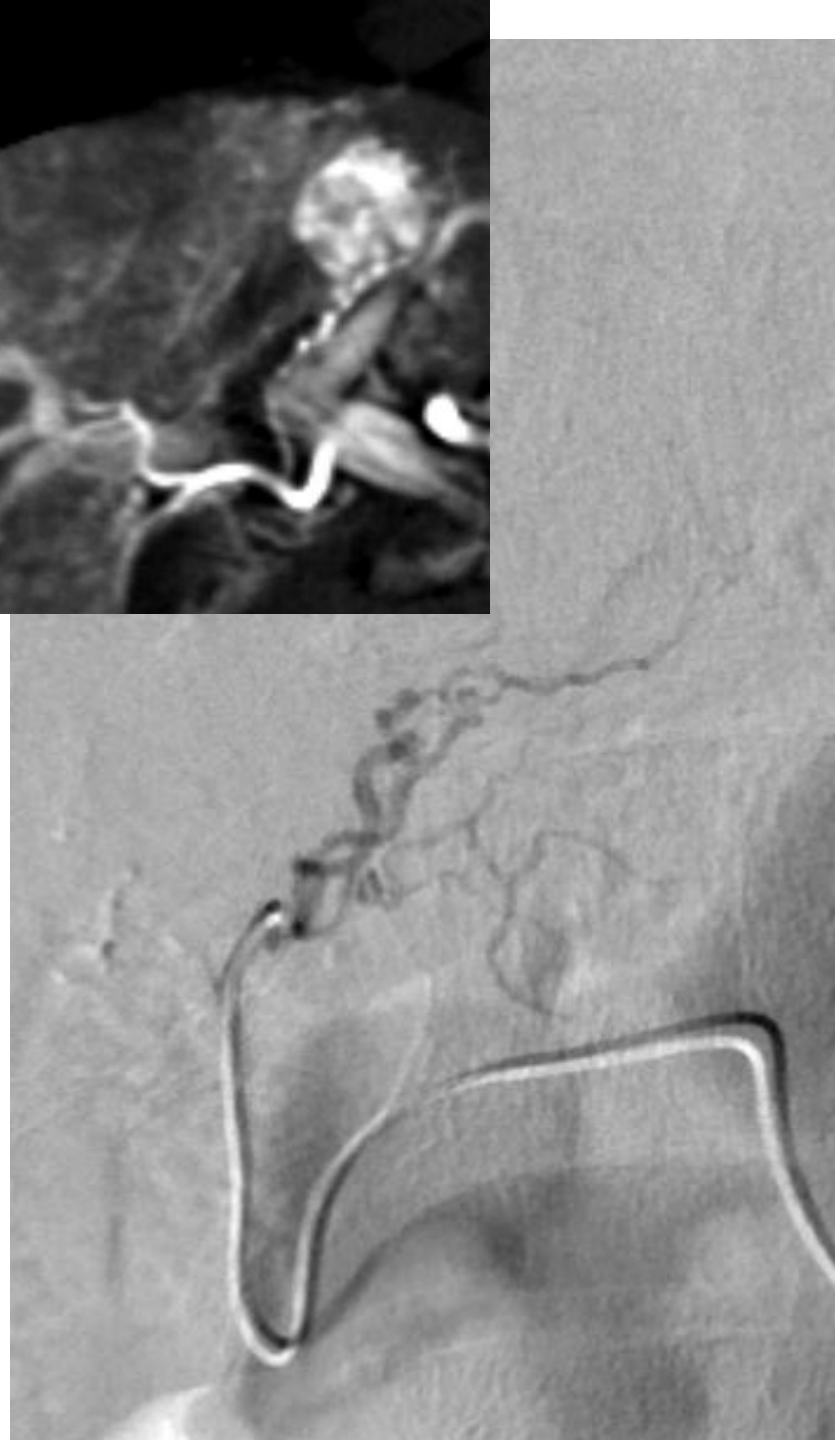
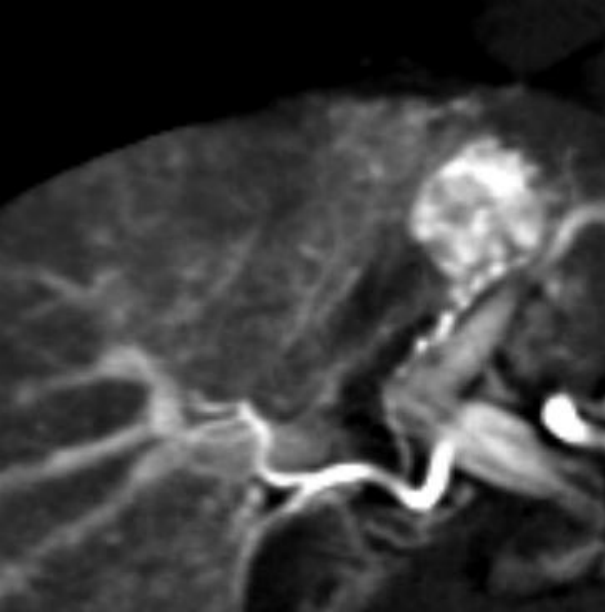
2012/01/21

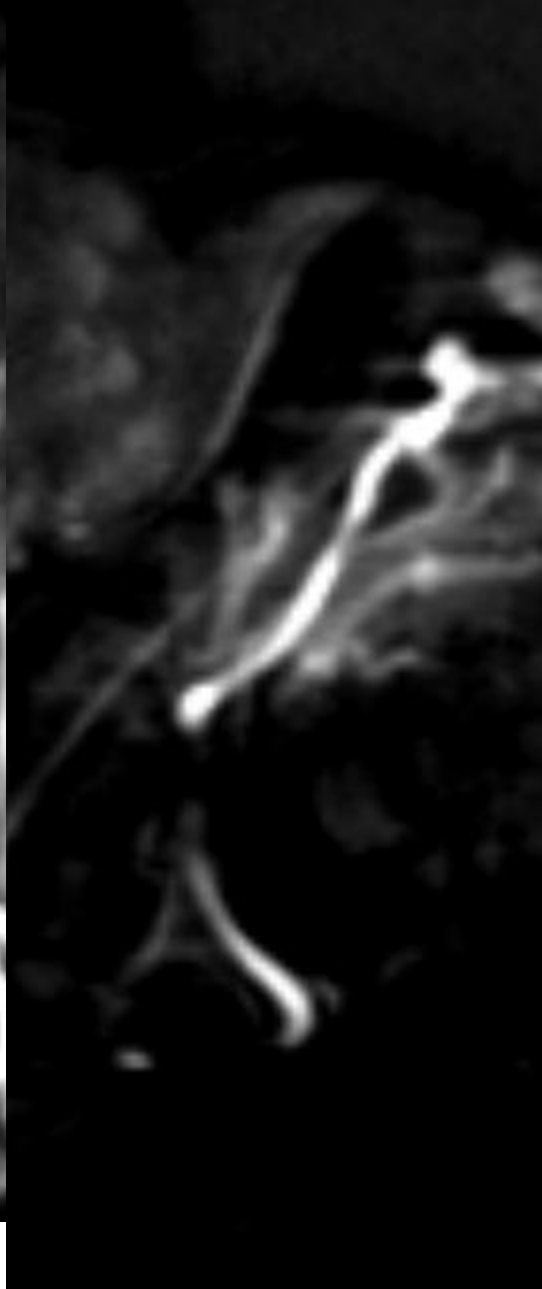
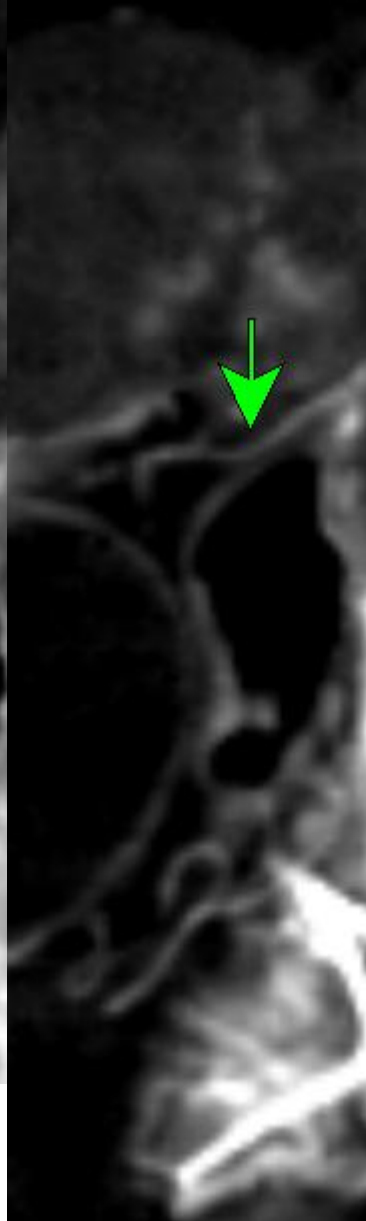
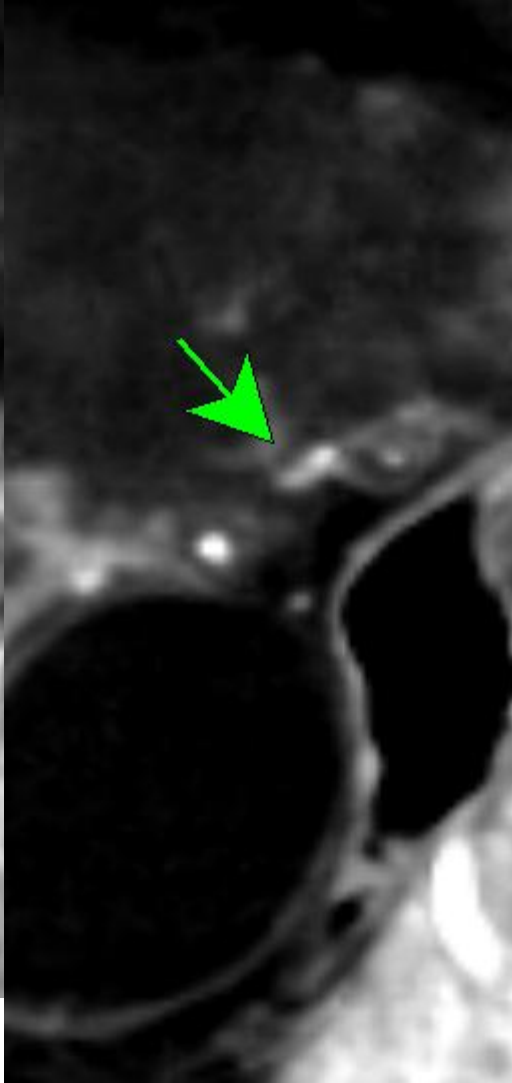
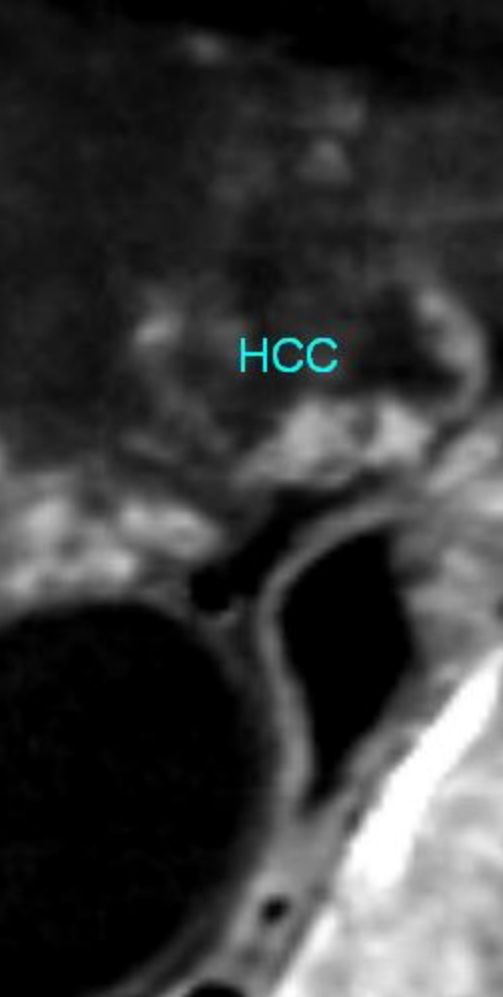


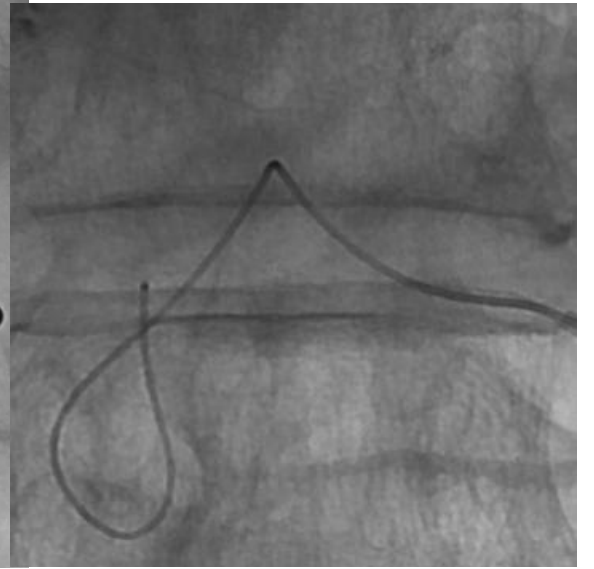
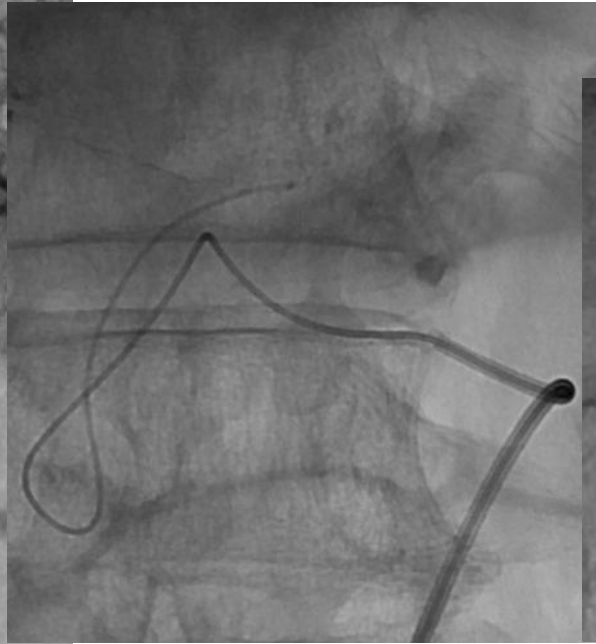
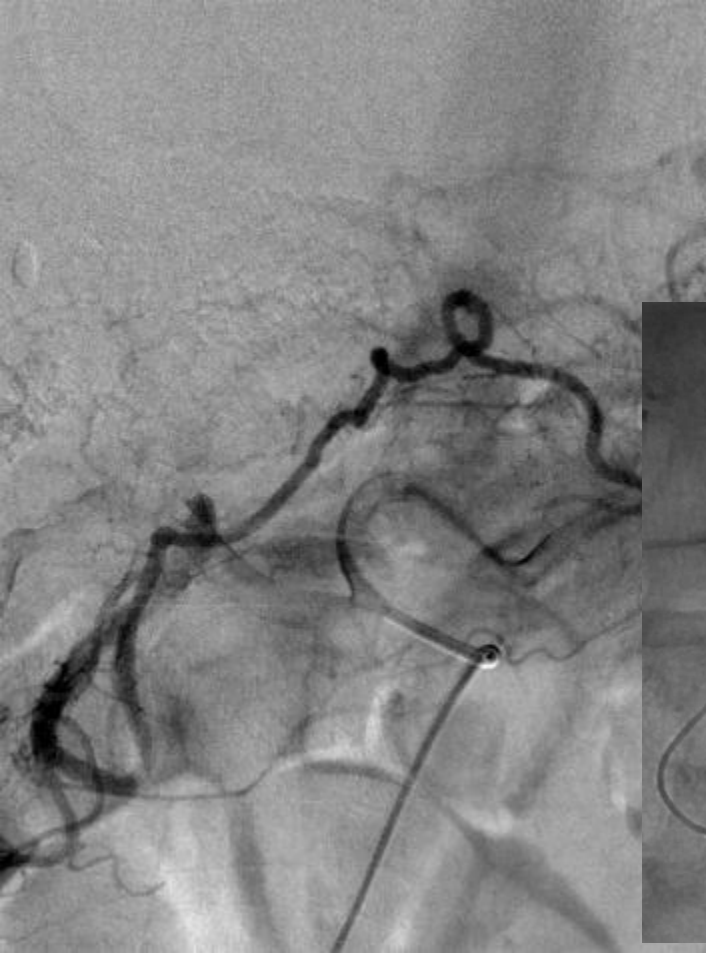

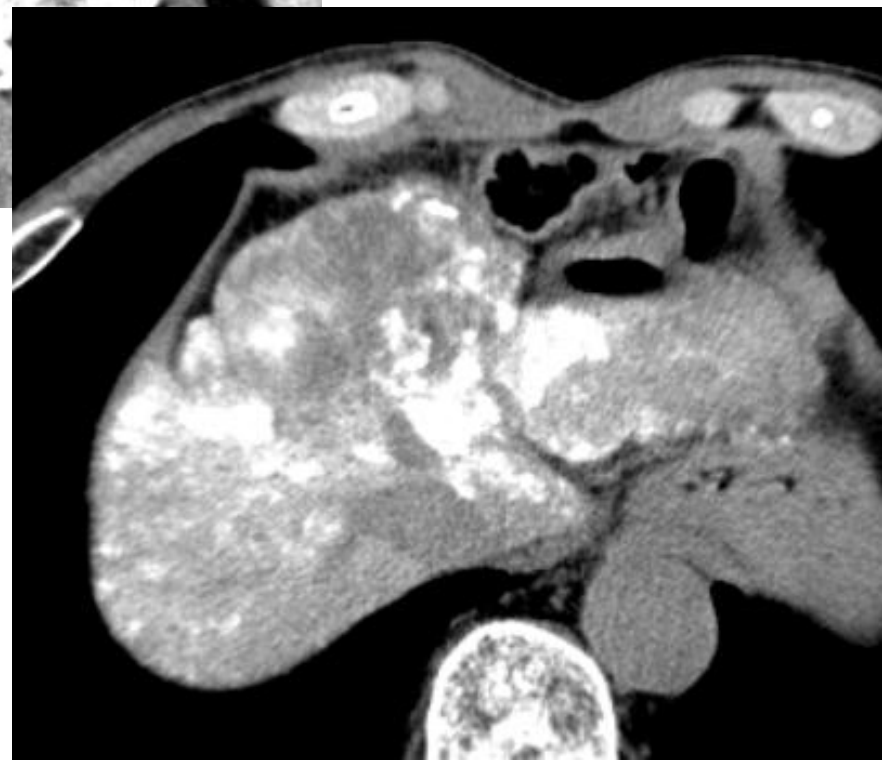
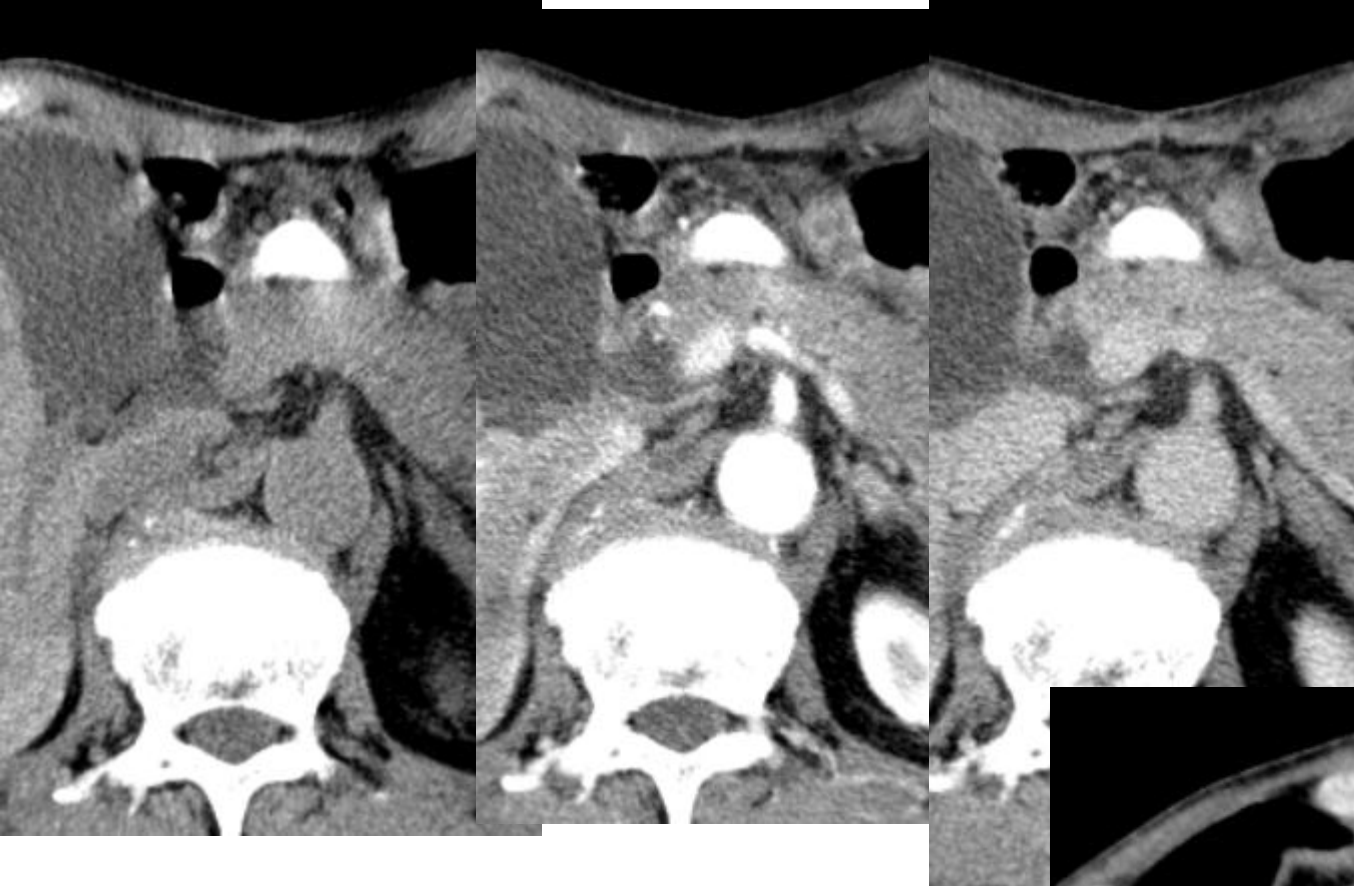



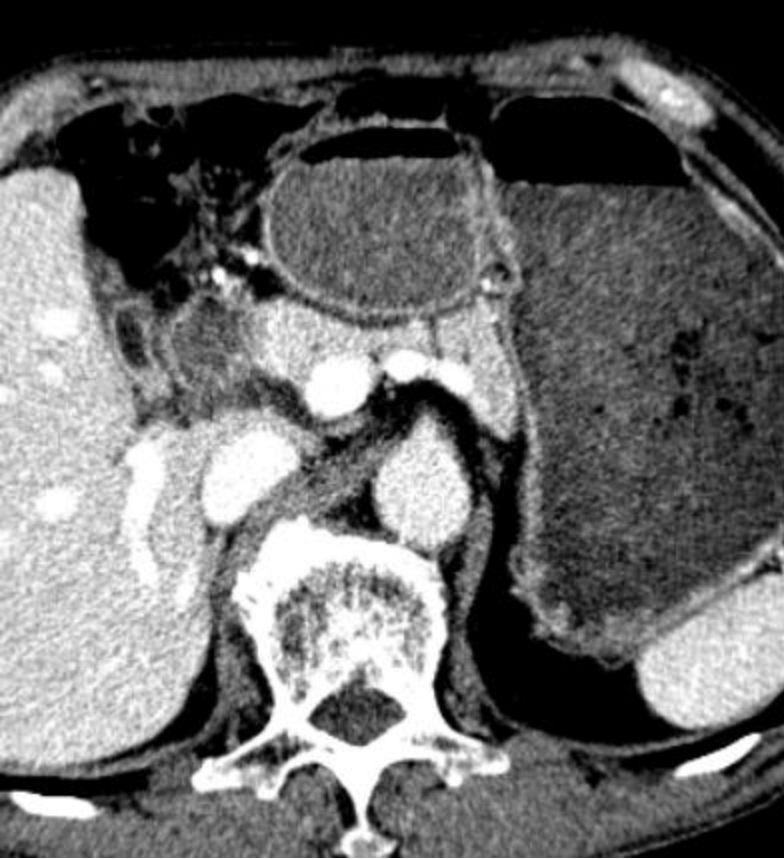










2012/05/19

